

dental  
bone & tissue  
regeneration

botiss  
biomaterials

# muco<sup>®</sup>derm

3D-regenerative tissue graft

Handling, clinical application and cases

native

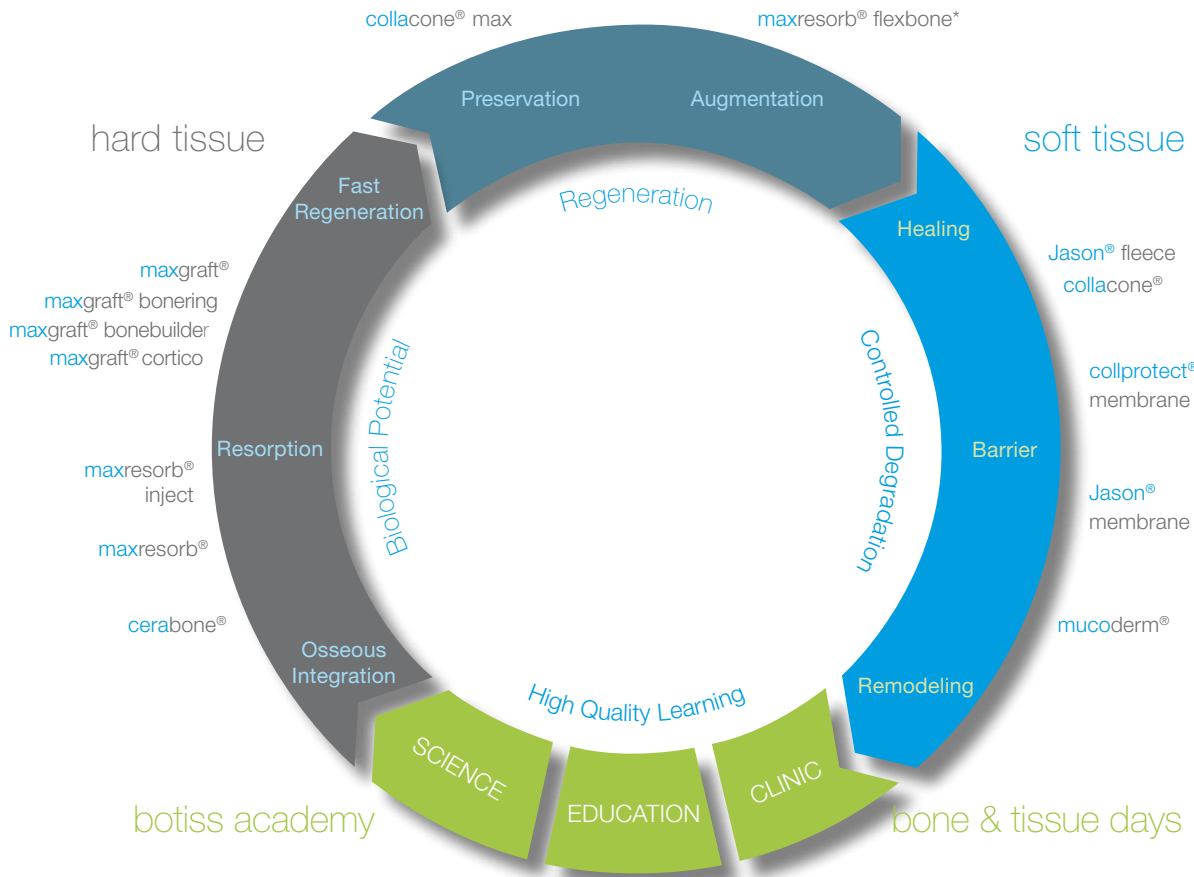
stable

three-dimensional

soft tissue



# botiss regeneration system



## Development / Production / Distribution



cerabone®

Natural bovine bone graft



maxresorb®

Synthetic biphasic calcium phosphate



maxresorb® inject

Synthetic injectable bone paste



maxgraft® bonebuilder

Patient matched allogenic bone implant



maxgraft® bonering / maxgraft® cortico

Processed allogenic bone ring / Processed allogenic bone plate



maxgraft®

Processed allogenic bone graft



collacone® max

Cone (CaP / Collagen composite)



maxresorb® flexbone\*

Flexible blocks (CaP / Collagen composite)



Jason® fleece / collacone®

Collagenic hemostypt (Sponge / Cone)



collprotect® membrane

Native collagen membrane



Jason® membrane

Native pericardium GBR / GTR membrane



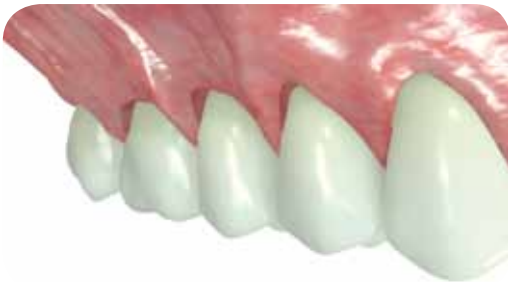mucoderm®

3D-stable soft tissue (Collagen) graft

# Periodontal surgery and soft tissue transplants

## Importance of plastic periodontal surgery

The growing demand for aesthetic procedures has recently led to an increase in the importance of plastic periodontal surgery, resulting in the development of new surgical techniques and concepts. Gingival recessions as well as reductions of the mucosa around pontics/dental implants or the reduced width of the keratinized gingiva may have a significant impact on the patient's aesthetics. Besides the aesthetic reasons, several indications require the treatment of soft tissue deficiencies.



## Clinical consequences of a soft tissue reduction

Despite the ongoing debate about the meaning of keratinized gingiva, most scientists and doctors agree that a sufficiently broad band of keratinized tissue exerts a positive effect on the tooth health and long-term prognosis of dental implants. Not only does the attached gingiva provide protection against mechanical traumas, but it also acts as a barrier against the penetration of bacteria and food particles. Studies have demonstrated that a reduction in the width of the keratinized gingiva is associated with an increased risk of infections, a loss of attachment, and higher plaque accumulation. Moreover, such situations may be the cause of the incidence of gingival recessions, which in turn may lead to hypersensitivity of tooth roots, root caries, and, in the worst cases, tooth loss.

## Mucosal and connective tissue transplants

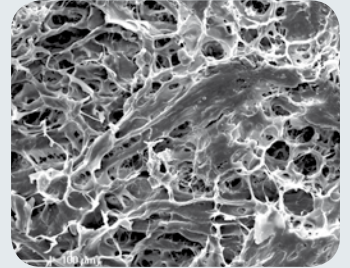
Today, modern techniques of plastic-aesthetic periodontal surgery ensure a predictable regeneration of soft tissue deficiencies in the majority of cases. Free mucosal transplants and subepithelial connective tissue grafts, both commonly harvested from the palate, are frequently used. Despite their clinical success, their use is associated with significant disadvantages; for instance, when harvesting the autologous transplant, a second surgical site is created, which may result in an increased post-operative pain as well as a higher risk of infections and complications. In addition, the quality of the harvested tissue varies from patient to patient, and its limited availability may be an issue, particularly for the correction of larger soft tissue defects or multiple recessions.

To spare the patient the harvesting of transplants from the palate, allogenic and xenogenic acellular collagen matrices have been developed. mucoderm® is the xenogenic matrix produced by botiss that offers a valid alternative for autologous soft tissue transplants.

# mucoderm®

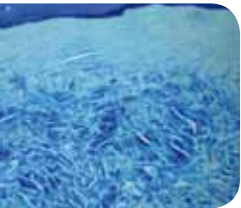
## Soft tissue graft

mucoderm® is a three-dimensional collagen tissue matrix derived from porcine dermis that undergoes a multi-step purification process, which removes all potential tissue rejection components from the dermis. This results in a three-dimensional stable matrix that consists of collagen and elastin. mucoderm® supports revascularization, fast soft tissue integration, and is a valid alternative to the grafts based on the patient's own soft or connective tissue.



The porous structure of mucoderm® surface enables the ingrowth of microvessels and soft tissue cells

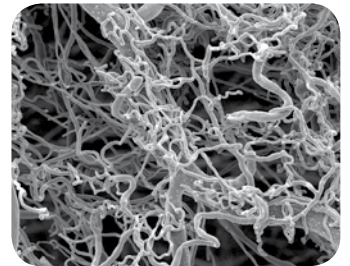
After placement, the patient's blood infiltrates the mucoderm® graft through the three-dimensional soft tissue network, bringing host cells to the soft tissue graft surface and starting the revascularization process. Depending on the health condition of the patient and other biological/non-biological factors, a significant revascularization may begin immediately after implantation.



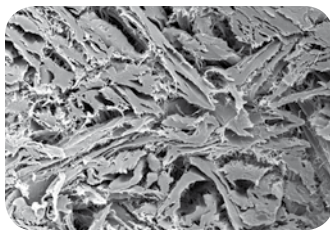
Histology of mucoderm® six months after implantation: Optimal integration and no inflammatory reaction

### Natural three-dimensional collagen tissue structure

The mucoderm® matrix is made of pure porcine collagen without artificial cross-linking or additional chemical treatment. Electron microscopic images of mucoderm® show its rough and open-porous collagen structure that guides soft tissue cells and blood vessels.



Corrosion preparation showing a vascular network running through the mucoderm® matrix



Compact collagen structure

### Properties and advantages

- Native collagen matrix
- Guided vascularization and integration
- Soft tissue graft without the need for autograft harvesting
- Complete remodeling into patient's own tissue in ~six to nine months
- Thickness ~1.2 to 1.7 mm
- Rapid rehydration
- Easy handling, application and fixation



# Handling of the mucoderm®

## General product handling

### Rehydration

A sufficiently long rehydration of mucoderm® prior to application is necessary. Rehydration should be performed in a sterile saline solution or blood for five to 20 minutes, depending on the technique used and the desired flexibility of the matrix—the flexibility of the mucoderm® graft increases with rehydration time.

### Trimming



Trimming of mucoderm® with a scalpel

The size and shape of the matrix should be adapted to the size of the defect. After rehydration, mucoderm® can be easily trimmed to the desired size with a scalpel or scissors. Cutting or rounding the edges of a mucoderm® matrix that has been briefly rehydrated can prevent the perforation of the gingival tissue during the flap closure. For the coverage of multi-recession defects, the surface of mucoderm® can be extended by cutting the matrix on alternating sides (mesh-graft technique) and pulling it.

### Exposure

mucoderm® should only be left for open healing, if a revitalization from the surrounding or underlying wound bed is ensured. Exposure should always be avoided when used in a recession coverage. Open healing is feasible in the case of a vestibuloplasty, if mucoderm® is sutured to the periosteum.



Perfect handling of mucoderm® after rehydration with blood

## Handling Tips

### Rehydration

from five to 20 minutes

### Trimming

use a scalpel or scissors to cut the desired shape

### Exposure

mucoderm® should only be left for open healing, if a revitalization from the surrounding or underlying wound bed is ensured

### Fixation

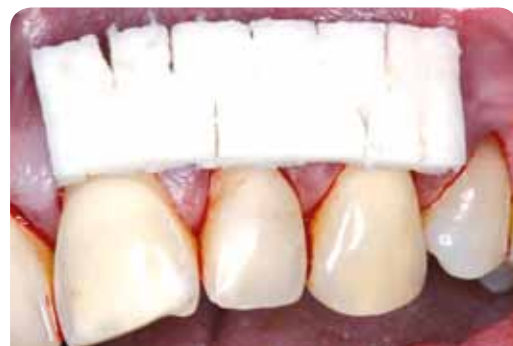suture of mucoderm® helps preventing micro-movements

### Fixation

When a split-thickness flap is used, a close contact between the periosteal wound bed and the immobilized mucoderm® matrix should be ensured by suturing the matrix to the intact periosteum using single-interrupted- or crossed sutures.

### Suturing

A tension-free closure is recommended for flaps.



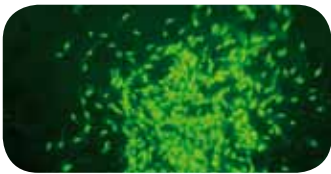
mucoderm® trimmed for application with the mesh-graft-technique

# Scientific results

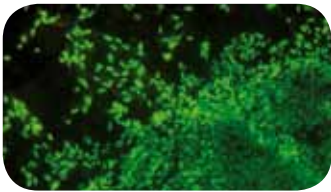


Biocompatibility proved by MTT *in vitro* viability assay testing<sup>1</sup>

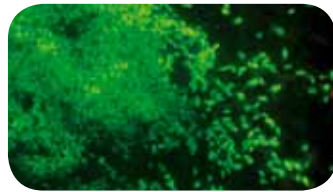
The viability assay proved the high biocompatibility of the mucoderm® three-dimensional collagen matrix.



Gingival fibroblasts on mucoderm®




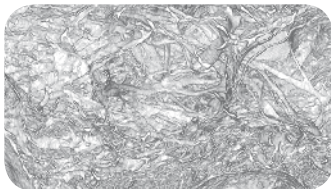
HUVEC cells on mucoderm®



Osteoblasts on mucoderm®

Beginning with day six, the MTT viability assay demonstrated a significantly higher viability of gingival fibroblasts, endothelial cells, and osteoblasts on mucoderm® compared to that of the control group ( $p < 0.05$ ).

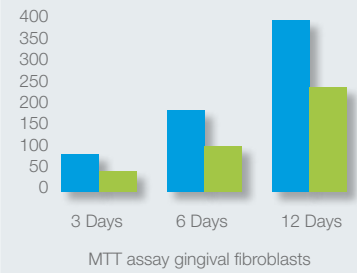
mucoderm® is characterized by an open porous collagen structure



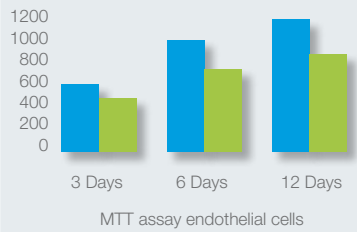
The open porous collagen structure of mucoderm® as visualized by the innovative synchrotron-based X-ray tomography<sup>2</sup>. The unique structure of the matrix strongly resembles that of the human dermis and supports the ingrowth of cells and blood vessels, thereby promoting a fast tissue integration of mucoderm®.

## *In vitro* testing

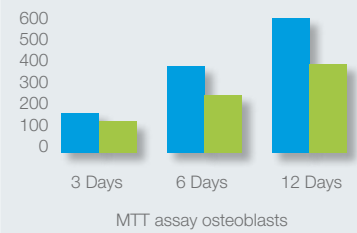
OD (optical density) viability of cells



OD (optical density) viability of cells



OD (optical density) viability of cells



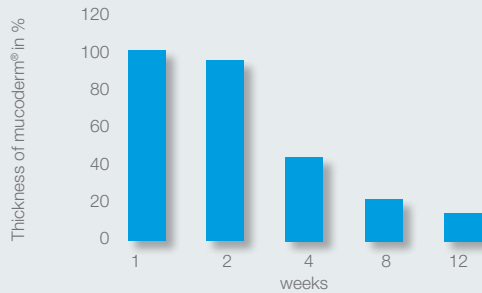
■ mucoderm®  
■ control

<sup>1</sup> Pabst et al. (2014): In vitro and in vivo characterization of porcine acellular dermal matrix for gingival augmentation procedures. In J Periodont Res 49 (3), pp. 371–381. DOI: 10.1111/jre.12115.

<sup>2</sup> Pabst et al. (2014): Synchrotron-based X-ray tomographic microscopy for visualization of three-dimensional collagen matrices. In Clinical oral investigations. DOI: 10.1007/s00784-014-1312-4.

# Tissue integration and degradation of mucoderm®

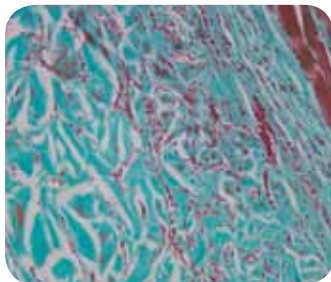
Results from PD Dr. Dr. Daniel Rothamel after subcutaneous implantation of mucoderm® in rats<sup>3</sup>



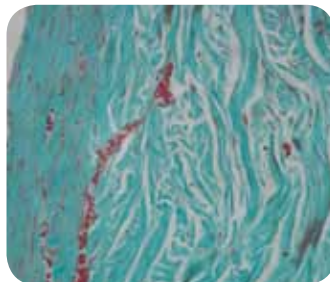
After only two weeks, mucoderm® shows an extensive in-growth of blood vessels as well as an inflammation-free healing with superficial cell invasion. In the following four to eight weeks, a continuous degradation with increasing homogeneous cell distribution can be observed. After eight weeks, still 20% of the original matrix volume is available as a scaffold for the formation and reorganization of connective tissue.

Degradation of mucoderm® after subcutaneous implantation in rats

After twelve weeks, mucoderm® is almost completely replaced by newly formed connective tissue (please note that a period of one month in rats corresponds to approximately three months in humans).

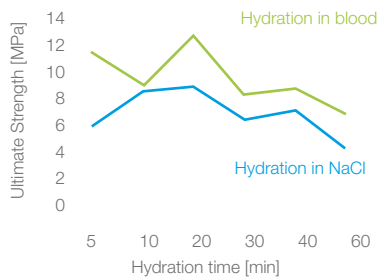


mucoderm® demonstrates a very good tissue integration and initial cell invasion after two-week healing time



Complete remodeling of mucoderm® and inflammation-free connective tissue are observed in vivo after 12 weeks

## Biomechanics and rehydration of mucoderm®



The rehydration protocol and its influence on the biomechanical properties of mucoderm® were analyzed in a study of PD Dr. Adrian Kasaj<sup>4</sup>. mucoderm® demonstrated optimal mechanical properties after ten to 20 minutes rehydration; in addition, rehydration in blood can improve the biomechanical properties of mucoderm®. Notably, prolonged rehydration (30 to 60 minutes) hardly affects the biomechanical properties of the collagen matrix.

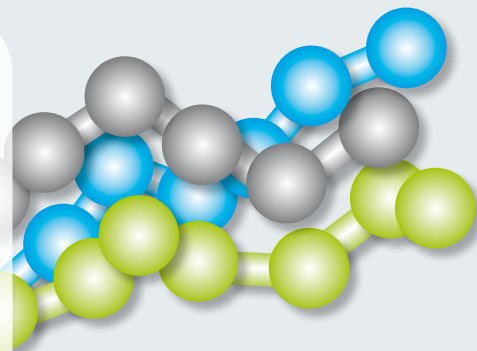


<sup>3</sup> Rothamel et al. (2014): Biodegradation pattern and tissue integration of native and cross-linked porcine collagen soft tissue augmentation matrices – an experimental study in the rat. In *Head Face Med* 10 (1), p. 10. DOI: 10.1186/1746-160X-10-10.

<sup>4</sup> Kasaj et al. The influence of various rehydration protocols on biomechanical properties of different acellular matrices. In *Clin Oral Invest.* 2015 Oct 5.

# Application of mucoderm® in plastic-aesthetic periodontal surgery

Not only are gingival recession defects an aesthetic issue, but they can also lead to clinical problems such as root hypersensitivity, cervical root caries, and root abrasion. Today, autologous connective tissue transplants are considered the “gold standard” for the treatment of periodontal recessions; however, harvesting is often a cause of further discomfort to the patient. The application of a regenerative tissue graft spares the patient the autologous connective tissue harvesting, thereby enhancing the patient’s acceptance of the surgical procedure.



Collagen  
triple helix

The correct application and handling of the graft material is a prerequisite to obtain predictable and optimal aesthetic and clinical results.

The following application guidelines, based on clinical results, have been developed together with Dr. Adrian Kasaj, specialist for Periodontology at the Department of Operative Dentistry and Periodontology at the University of Mainz.

## Selection of patients

mucoderm® offers a safe and effective alternative for the coverage of recession defects, especially when patients do not agree to undergo palatal autograft harvesting. Nevertheless, expectations concerning the clinical and aesthetic outcome of the surgery should be carefully considered and discussed with the patient. The patient compliance with the post-operative treatment plan, as well as an unimpaired or controlled state of health, is indispensable for the success of the treatment.

## Product Specifications

Irrespective of the applied technique, the clinical success of the treatment of Miller class I/II defects is more predictable than that of class III/IV defects. In principle, a complete recession coverage could only be obtained for Miller class I/II defects. Likewise, the predictability and success rate for the

treatment of defects in the maxilla are higher as compared to those of mandibular defects. mucoderm® can be used in combination with all mucogingival surgery techniques, including coronally advanced flap and envelope technique.

## Post-operative treatment

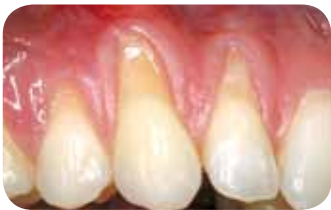After surgery it is necessary to avoid any mechanical trauma of the treated site. Patients should be instructed not to brush their teeth at the respective side for the four weeks following surgery. Plaque prevention can be achieved by mouth rinsing with a 0.2% chlorhexidine solution. Post-operatively, the patient should be recalled weekly for plaque control and healing evaluation.



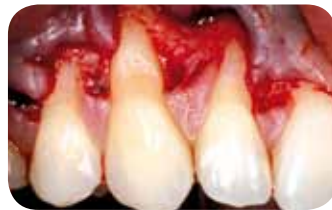# Clinical application of mucoderm®

PD Dr. Dr. Adrian Kasaj, University of Mainz, Germany

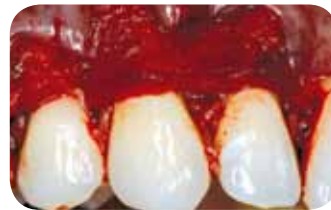## Recession coverage with the modified coronally advanced flap technique (zucchelli technique)



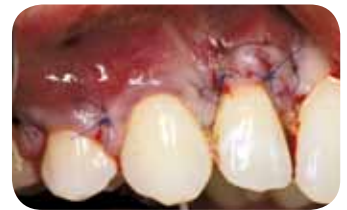Multiple gingival recessions at teeth 12,13, and 14 before treatment with mucoderm®



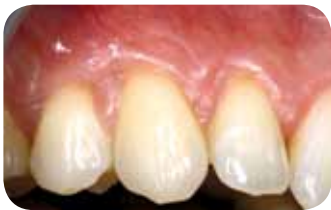A sulcular incision from tooth 11 to 15 is made and a split-thickness flap is raised



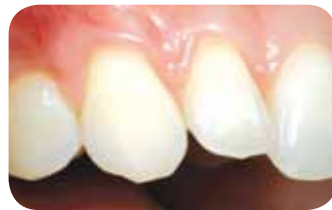mucoderm® is rehydrated, trimmed, and placed over the denuded roots



The flap is coronally repositioned over the root surfaces and the mucoderm® matrix



3 months post-operative:  
Significant coverage of roots and increased thickness of marginal tissue

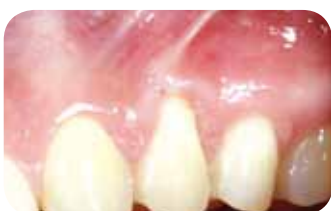

Clinical situation 18 months post-operative

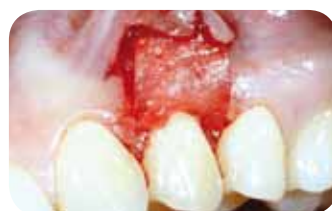### Handling Tips

- Contact of mucoderm® with the periosteal wound bed and immobilization should be ensured by suturing the matrix to the periosteum using single-interrupted- or all-crossed sutures
- Cutting the edges of a briefly rehydrated matrix prevents damage of the gingival tissue during flap closure

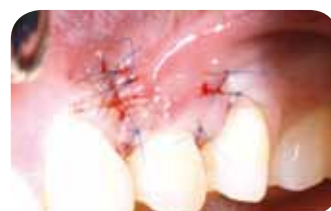## Recession coverage with mucoderm® with the coronally advanced flap technique



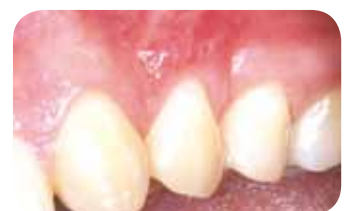Initial situation with gingival recession and muscle strain on tooth 24



mucoderm® rehydrated, cut-to-shape, and sutured to the periosteum



Repositioning and suturing of the flap over mucoderm® and the tooth root

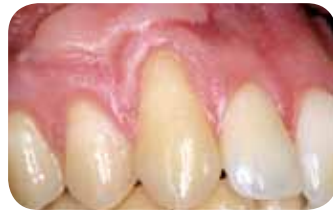

Situation after three-months healing

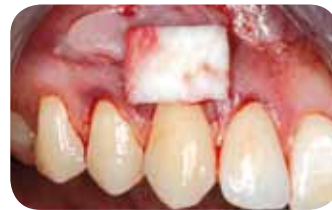# Clinical application of mucoderm®

PD Dr. Dr. Adrian Kasaj, University of Mainz, Germany

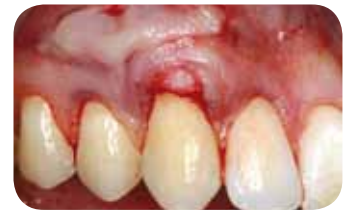Recession coverage with mucoderm® by the envelope technique



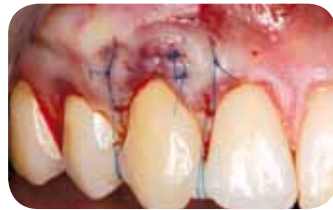Gingival recession at tooth 13 before the treatment with mucoderm®; FST of a previous surgery for root coverage visible



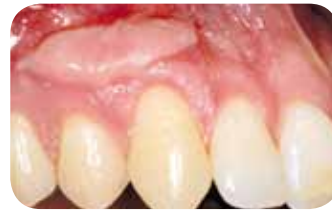mucoderm® is rehydrated and cut to shape for placement over the root



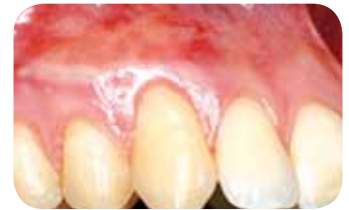A subepithelial pouch is prepared by a partial thickness incision; mucoderm® is placed under the pouch



After the positioning of mucoderm®, the flap is fixed to completely cover the graft

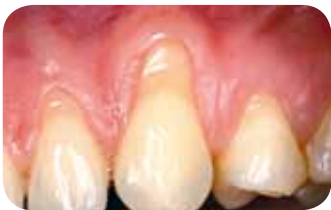

Clinical situation three months after treatment: significant root coverage and increased thickness of marginal tissue

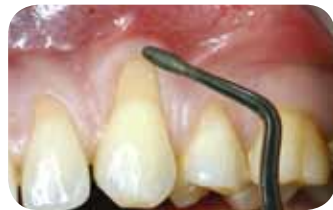

Situation after gingival plastic for leveling of the FST

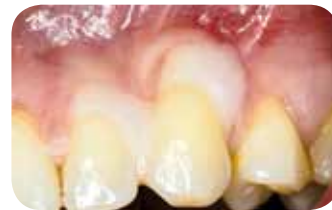Covering of multiple recessions with mucoderm® by the tunnel technique



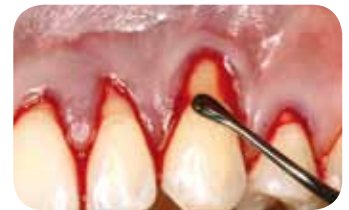Clinical view before treatment with mucoderm®; gingival recessions at teeth 23 and 24



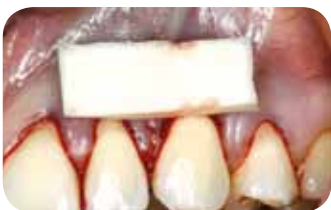Preparation of roots by scaling and planning with sonic scaler



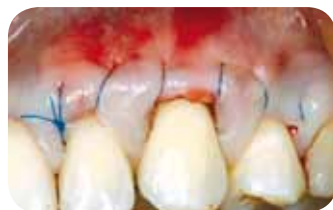Conditioning of roots with 24% EDTA gel for two minutes



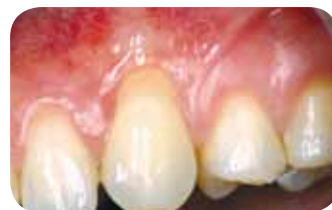Sulcular incisions around teeth 22 to 25; a partial-thickness dissection by undermining the papillae using tunneling instruments



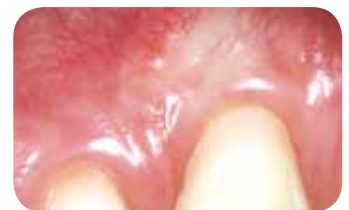Rehydrated and trimmed mucoderm® is checked to fit into the defect; mucoderm® is placed over the roots by pulling it through the tissue tunnel



The flap is repositioned over the mucoderm® matrix and sutured



Three months post-operative: previously exposed roots are significantly covered; in addition, the thickness of the marginal tissue has increased



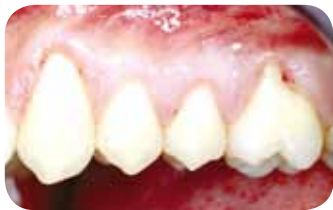Clinical situation 12 months post-operative

# Clinical application of mucoderm®

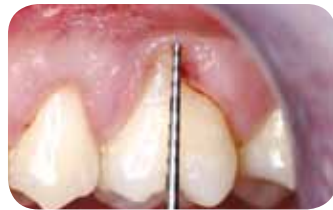Dr. Dávid Botond Hangyási,

University of Hódmezővásárhely-Szeged, Hungary

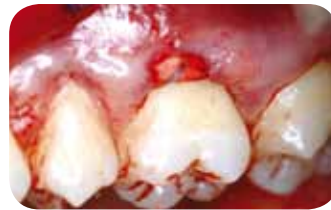## Recession coverage with mucoderm®



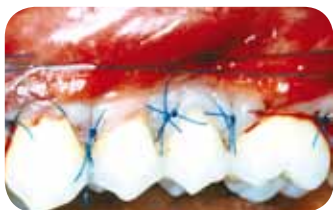Pre-operative clinical situation



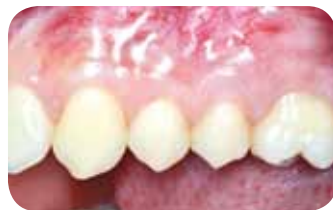Pre-operative clinical situation, measurement of the recession depth



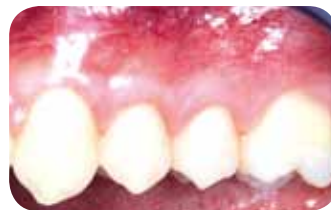Modified coronally advanced tunnel technique with mucoderm®; dermal matrix pulled into the tunnel



Repositioning and suturing of the flap over the mucoderm® and the tooth roots



Situation after three-months healing



Clinical outcome three years post-operative

### Handling Tips

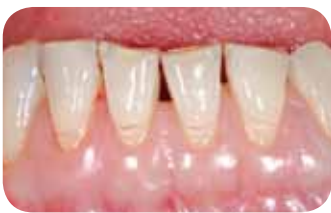- Exposure of the mucoderm® matrix should always be avoided in treatment of gingival recessions. Make sure that the repositioned flap completely covers the mucoderm® matrix. Achieving primary closure over the mucoderm® graft allows blood vessels to penetrate and incorporate the soft tissue graft material. Early exposure may lead to soft tissue graft failure.

# Clinical application of mucoderm®

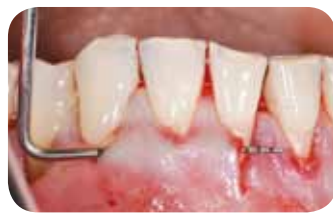Dr. Raluca Cosgarea, University of Cluj-Napoca, Romania and

Prof. Dr. Dr. Anton Sculean, University of Bern, Switzerland

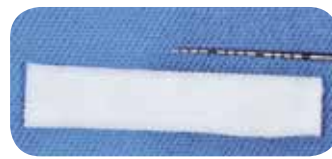Covering of multiple recessions in the lower jaw with the modified tunnel technique and mucoderm®



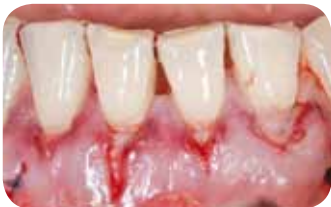Situation before surgery



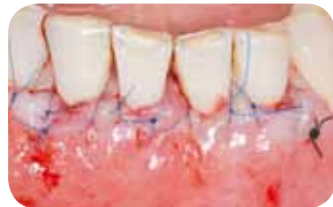Preparation of the tunnel



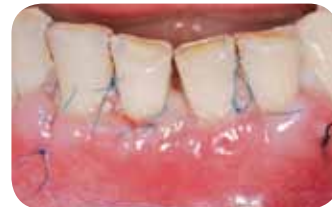Rehydration of mucoderm® and cutting to shape



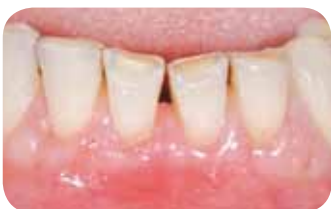mucoderm® inserted into the tunnel and sutured



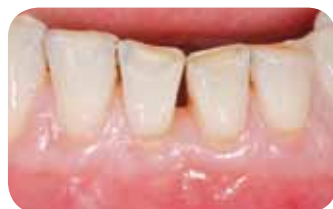Repositioning of the flap over the mucoderm® and suturing



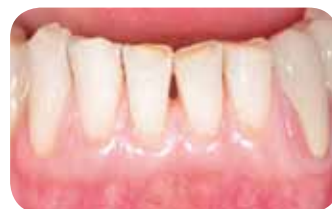Healing after one week



Healing at suture removal after four weeks



Healing after two months

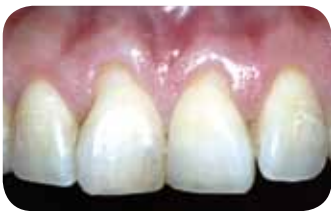

Healing after 12 months

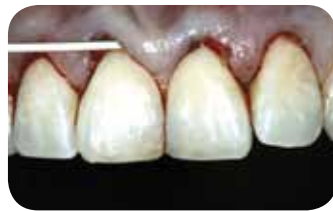# Clinical application of mucoderm®

Dr. Markus Schlee, Forchheim, Germany

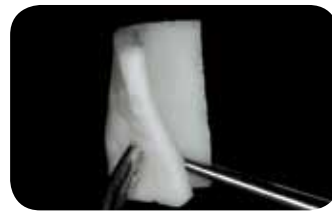## Recession coverage with mucoderm® with the tunnel technique



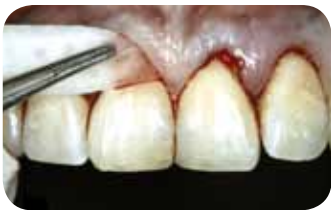Clinical situation before treatment with mucoderm®; gingival recession at teeth 11 and 21



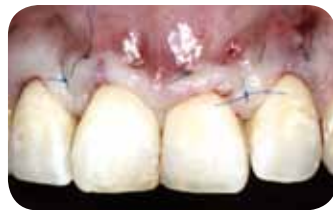Sulcular incision around teeth 12 to 22; partial thickness dissection by undermining the papillae as performed with tunneling instruments



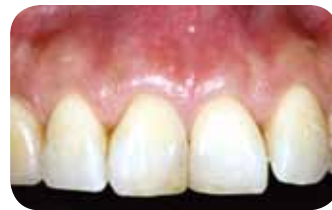mucoderm® is rehydrated for about ten minutes until the desired flexibility is obtained



Rehydrated mucoderm® is cut to shape and inserted under the papillae



Repositioning of the flap over mucoderm® and the tooth roots



Significant coverage of the roots and healthy gingiva one year after surgery

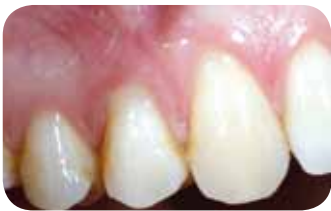### Handling Tips

- For the tunnel technique, a prolonged (ten to 20 minutes) rehydration of mucoderm® is recommended.
- Fixation of the matrix by single-interrupted- or all-crossed sutures is required.

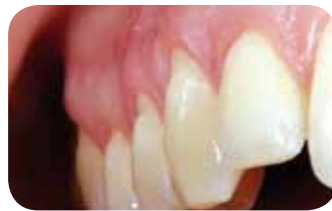# Clinical application of mucoderm®

PD Dr. Dr. Adrian Kasaj, University of Mainz, Germany

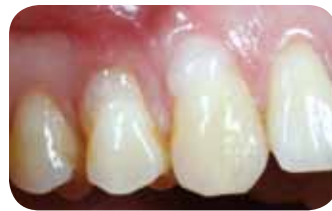Recession coverage with a coronally advanced flap technique with a combination of mucoderm® and Straumann® Emdogain®



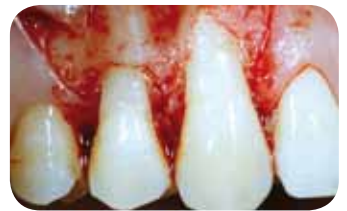Situation before surgery with recessions at teeth 13 and 14



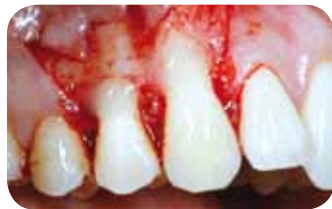Baseline clinical situation, lateral view



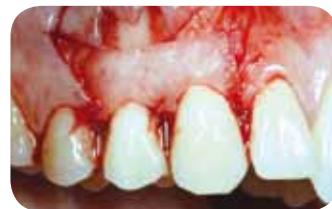Root surface conditioning with 24% EDTA gel



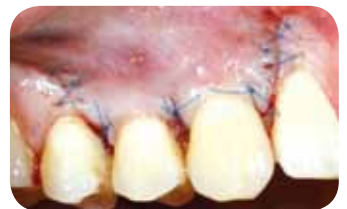Preparation of a flap with vertical releasing incisions



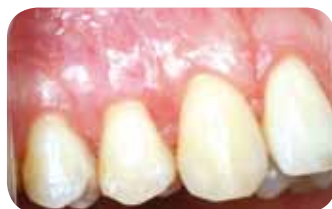Application of Straumann® Emdogain® to the root surface



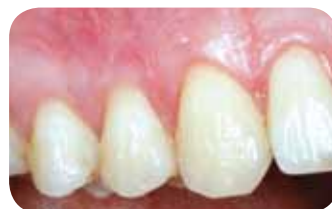Rehydrated mucoderm® cut-to-shape, adapted to the donor bed, and sutured to the periosteum



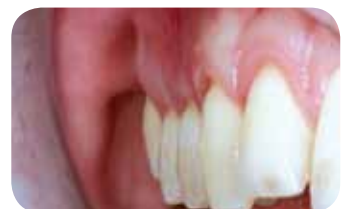Coronal repositioning and suturing of the flap over mucoderm® and the roots



Healing after six weeks



Clinical situation three months post-operative

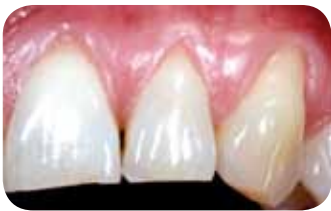

Clinical situation three months post-operative, lateral view

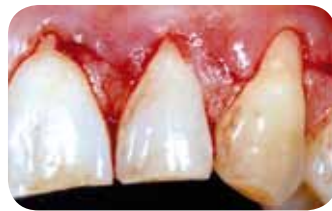# Clinical application of mucoderm®

PD Dr. Dr. Adrian Kasaj, University of Mainz, Germany

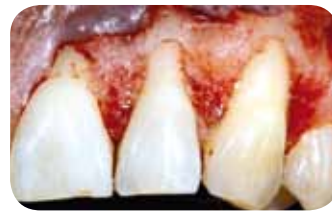Recession coverage with a combination of mucoderm® and Straumann® Emdogain®



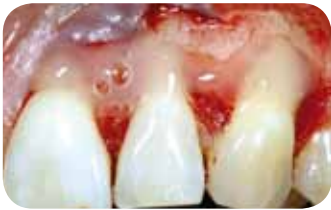Multiple gingival recessions at teeth 21, 22 and 23 prior to treatment



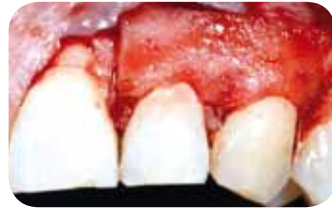Sulcular incision from teeth 21 to 23



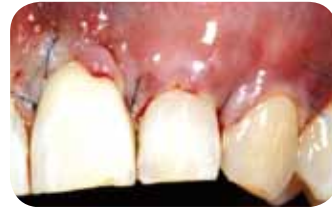Preparation of a split-full-split thickness flap and de-epithelialization of the anatomical papillae



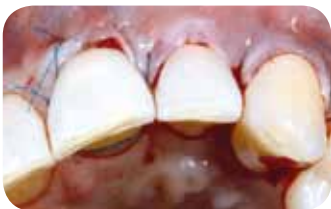Application of Emdogain® to the conditioned root surface



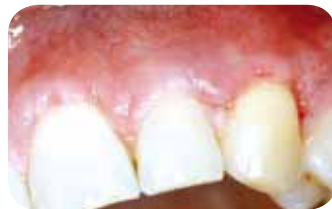Adaptation of the rehydrated and cut-to-shape mucoderm®, and suturing to the periosteum



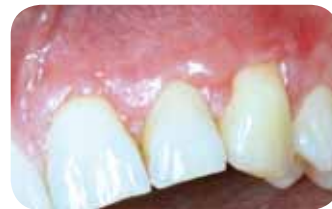Repositioning of the flap over mucoderm® and the root surface



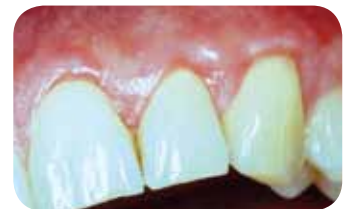Wound closure, occlusal view



Healing four weeks after surgery



Clinical situation eight weeks post-operative



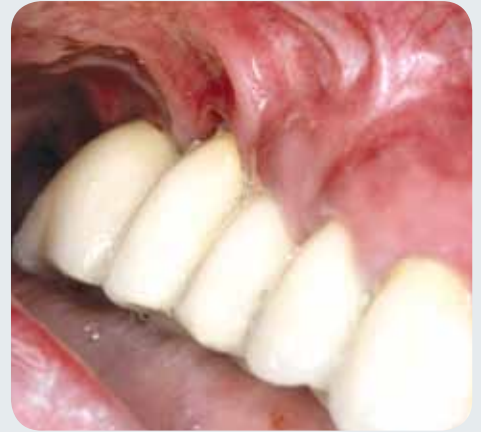Satisfactory coverage of the roots and thickening of the marginal gingiva, five months post-operative

## Handling Tip

- Emdogain® can be directly applied to the tooth roots and then covered with mucoderm®. Alternatively, mucoderm® may be coated with Emdogain® prior to application.

# Attached gingiva—protection of teeth and implants

Under healthy conditions, the teeth are lined by a band of attached gingiva of about five millimeters in width, which is anchored to the underlying alveolar bone and cementum through connective tissue fibers. This particular arrangement creates a barrier around the teeth, protecting the tooth roots against penetration of bacteria and food particles.



Moreover, the attached gingiva absorbs the mechanical strain from the lip-, cheek-, and mimic muscles, shielding the teeth from the strain. A reduction or lack of attached gingiva may cause root recessions and inflammation (periodontitis), which may lead to bone resorption and tooth loss.

Likewise, a sufficient width of the attached gingiva around the dental implants may improve their survival by facilitating the plaque control in the peri-implant area and preventing recessions at the implant. In particular, prior to or immediately after an implantation, an augmentation of the attached gingiva is indicated.

## Augmentation of the attached gingiva

The current standard technique to widen the attached gingiva is vestibuloplasty, performed in combination with a free mucosal graft<sup>5</sup>. Following the preparation of a mucosal flap, the soft tissue graft is fixed to the exposed periosteum (donor bed) and left for open healing.

However, the harvesting of the graft presents an additional stress for the patient and may cause further post-operative discomfort, an increased risk of swelling, post-operative bleeding, paresthesia, and inflammation<sup>6</sup>. In some cases, post-operative discomfort may persist for several weeks.

The application of a xenogenic collagen matrix, such as mucoderm<sup>®</sup>, may spare the patient the harvesting procedure and consequently increase the acceptance for the treatment plan.

## Application of mucoderm<sup>®</sup> in place of a free mucosal graft

The mucoderm<sup>®</sup> matrix may be applied in analogy to a free mucosal graft for the coverage of the prepared donor bed during a vestibuloplasty. Following rehydration and shaping, the matrix is adapted to the periosteum and fixed with sutures.

A close contact between the periosteum and mucoderm<sup>®</sup> is necessary to ensure a fast integration and revitalization of the matrix by the ingrowth of blood vessels and cells. mucoderm<sup>®</sup> serves as a scaffold for the formation of connective tissue and is completely remodeled into the patient's own tissue within weeks following surgery.

5 Fröschl and Kerscher (1997): The optimal vestibuloplasty in pre-prosthetic surgery of the mandible. In Journal of Cranio-Maxillofacial Surgery 25 (2), pp. 85–90. DOI: 10.1016/S1010-5182(97)80050-9.

6 Griffin et al. (2006): Postoperative complications following gingival augmentation procedures. In J Periodontol 77 (12), pp. 2070–2079. DOI: 10.1902/jop.2006.050296.



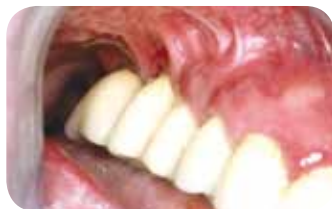# Augmentation of the attached gingiva with mucoderm®

## Results from a clinical study

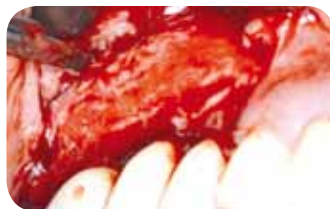Dr. Dr. Andres Stricker, Konstanz, Germany<sup>7</sup>

Dr. Dr. Andres Stricker investigated the efficiency of mucoderm® for the augmentation of keratinized peri-implant gingiva. The width of the keratinized gingiva as well as the health of the peri-implant tissue and the patient morbidity were assessed up to twelve months post-operatively.

Six months post-operatively, a significant widening of the attached gingiva and improved health of the peri-implant tissue were observed. The clinical situation was stable and could be confirmed after 12 months.



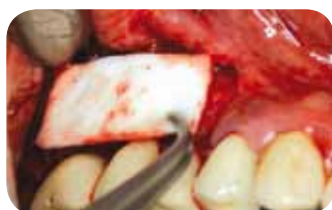Clinical situation: lack of keratinized gingiva



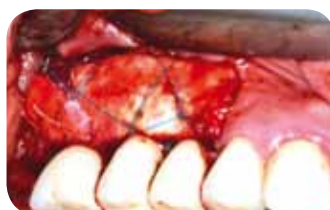Preparation of a mucosal flap



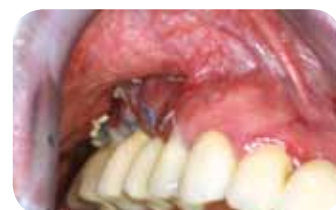Rehydration of mucoderm® in sterile saline



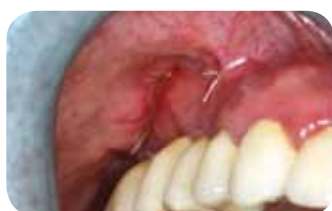Adaptation of mucoderm® to the recipient site



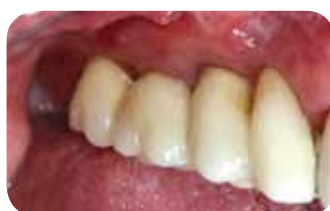mucoderm® sutured to the periosteum



Clinical situation after two weeks



Clinical situation after four weeks



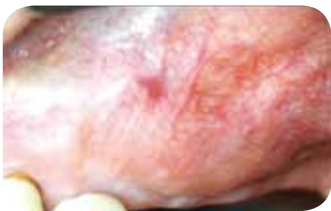Clinical situation after three months

<sup>7</sup> Stricker et al. 2014, Evaluation of a porcine collagen matrix to create new keratinized tissue at deficient implant sites: 12 months results from a controlled prospective clinical study. Clin Oral Implants Res. 2014 Sep;25 Suppl. 10:490

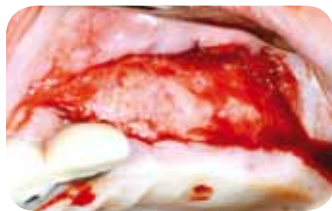# Clinical application of mucoderm®

Dr. Attila Horváth, Semmelweis University, Budapest, Hungary<sup>8</sup>

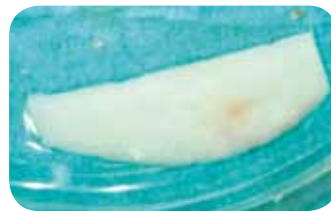Treatment with mucoderm® to increase the peri-implant keratinized mucosa



Lack of sufficient keratinized mucosa is visible as a result of considerable horizontal ridge augmentation



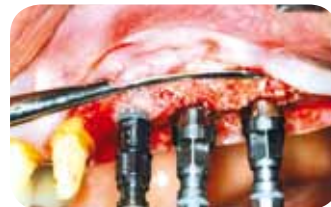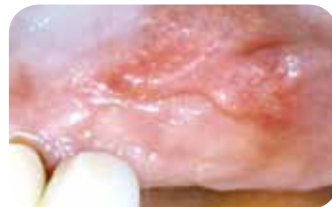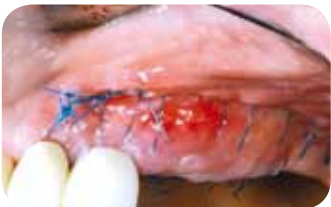The split-thickness flap was prepared; the buccal peri-implant mobile mucosa was positioned apically, creating an immobile periosteal recipient bed



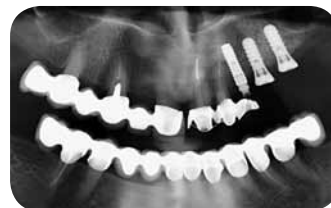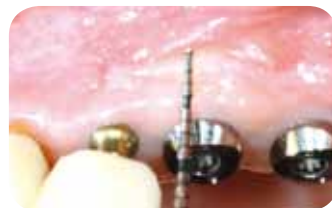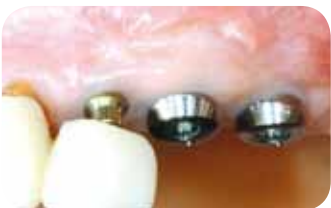The xenogenic dermal matrix (mucoderm®) was trimmed and rehydrated in sterile saline



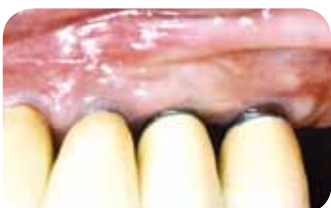mucoderm® was immobilized with modified deep periosteal and superficial mattress sutures to attain a tight contact to the periosteum



No allergy, rejection, suppuration, or ulceration were detected; following maturation of the graft, three Straumann SLActive® implants were inserted according to the prosthetic indication



Sufficient peri-implant keratinized mucosa and deep vestibulum were achieved around all implants



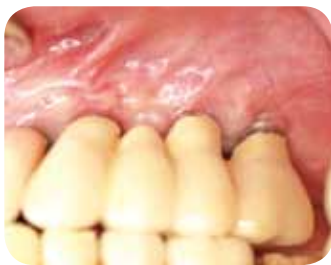Six months after insertion of the xenogenic dermal matrix, the new peri-implant keratinized mucosa showed matured and stable properties

<sup>8</sup> Horvath et al., Comparison of different approaches aiming at increasing peri-implant keratinized mucosa. ITI WS 2014 Poster presentation

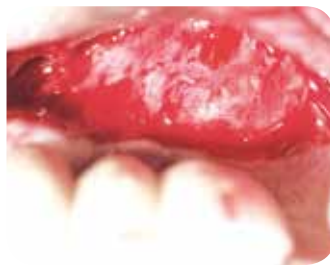# Clinical application of mucoderm®

Prof. Gregor-Georg Zafiropoulos, Düsseldorf, Germany

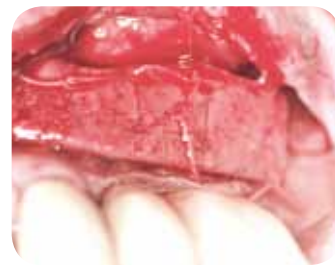
Augmentation of the attached gingiva with mucoderm®



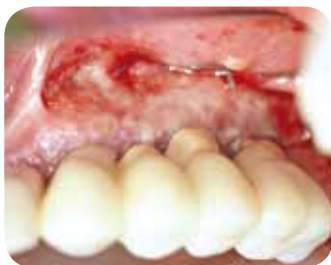Implant-based bridge in regio 23 to 26 with a very narrow band of the attached gingiva



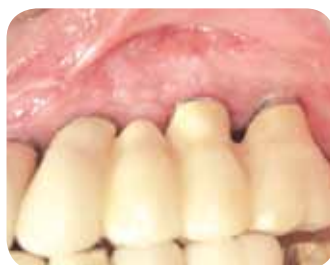Preparation of a mucosal flap starting at one millimeter para-marginally



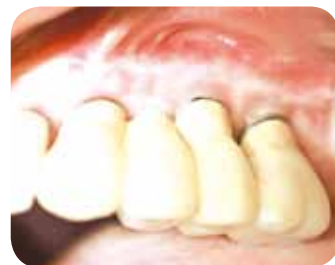mucoderm® fixed to the periosteum with resorbable sutures and left for open healing; the mucosal flap fixed coronally with non-resorbable sutures



Tissue formation ten days after surgery



Clinical situation four weeks post-operative, demonstrating a band of attached gingiva of about six millimeters in width




Stable clinical situation one year after surgery

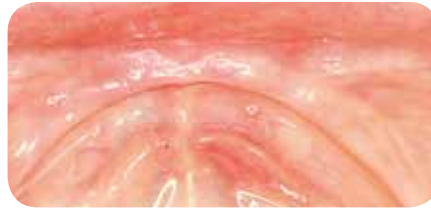# Clinical application of mucoderm®

Dr. Dávid Botond Hangyási, University of Szeged, Hungary

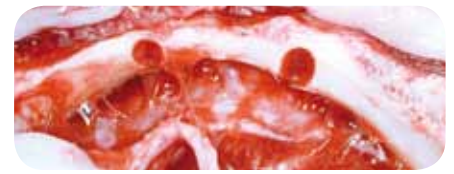Ridge augmentation with later soft tissue augmentation with mucoderm®



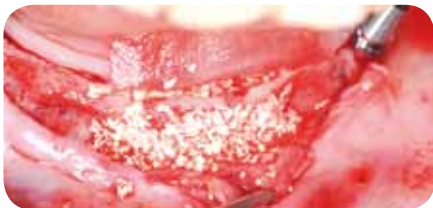CBCT planning for navigated implantology



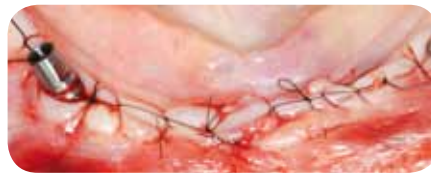Pre-operative clinical view of the surgical field



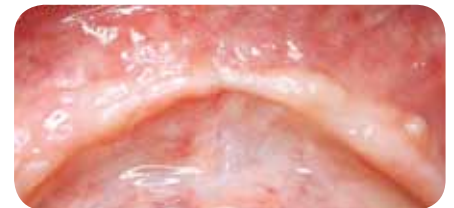Mandibula ridge found to be thinner than expected; placing the implants is not feasible



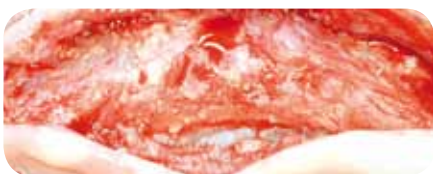Modified "sausage technique": Horizontal ridge augmentation (GBR) with a combination of autologous bone particles and cera-bone® covered with Jason® membrane and fixed by resorbable periosteal sutures



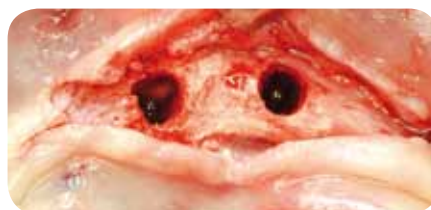Flap closure with 6/0 monofil continuous sling sutures



Post-operative clinical view six months after GBR



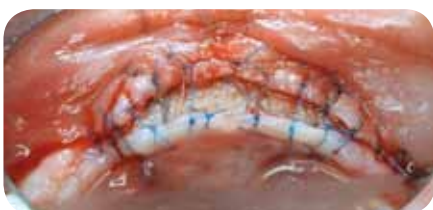Newly generated mandibular ridge at the time of the re-entry



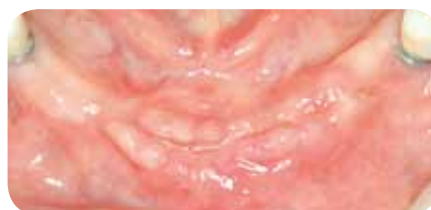Appropriate amount of bone for standard-size implants



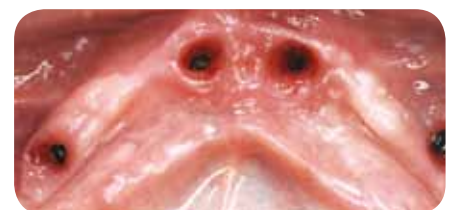Thick mucoderm® (~three millimeters) ready for gingival augmentation



Periosteum closed over the submerged implants and covered with mucoderm®; flap is sutured to the dermal matrix (6/0 monofil sutures), mucoderm® partially left uncovered



Clinical view three weeks after the second surgery

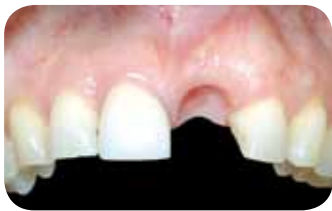

Gingival contour five months after implantation; sufficient amount of keratinized gingiva around implants

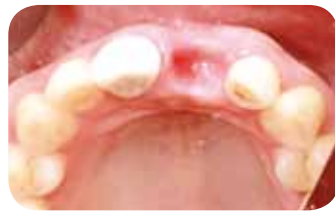# Clinical application of mucoderm®

Stefan Scherg, Karlstadt, Germany

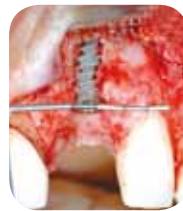GBR and simultaneous soft tissue augmentation  
with mucoderm®



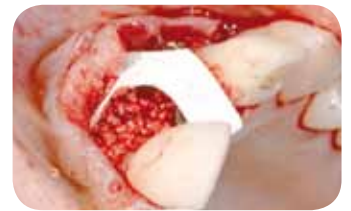Clinical situation before surgery, vestibular view



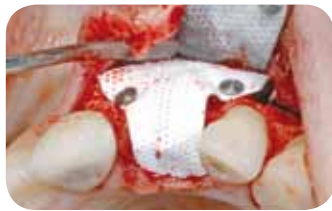Clinical situation before surgery, crestal view



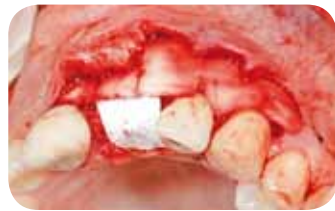Situation after implantation, demonstrating a buccal defect



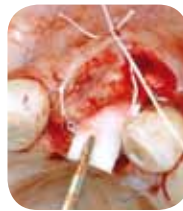Augmentation with maxresorb® and covering with a non-resorbable PTFE membrane



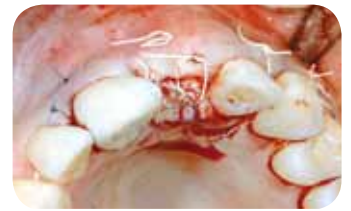Fixation of the membrane with titanium pins



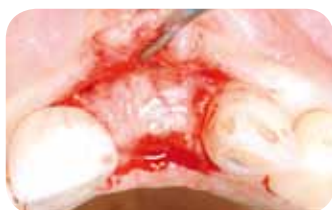Soft tissue thickening of the buccal side with mucoderm® and recession treatment of tooth 23



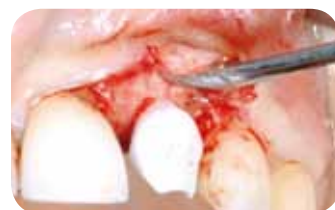Additional placement of mucoderm®, crestally and lingually



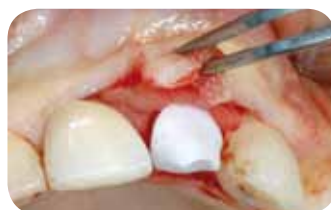Fixation of mucoderm® and suturing of the flap



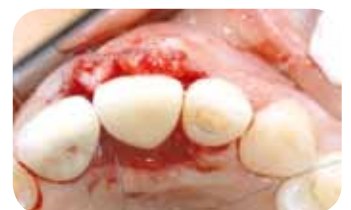Implant exposure and membrane removal four months post-operative



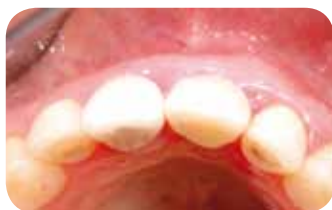Abutment insertion



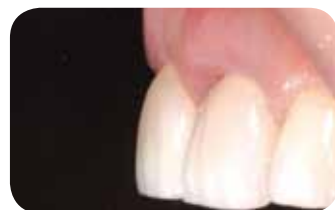A new soft tissue augmentation with mucoderm®



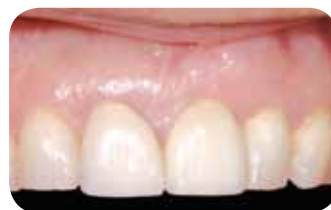Wound closure and mounting of provisional prosthesis



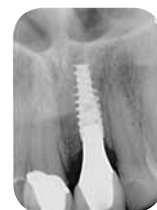Situation after long-term healing with provisional prosthesis



Definite restoration 15 months after implantation and stability of root coverage in region 23



Definite restoration 15 months after implantation



X-ray control 15 months post-operative

# The socket seal technique

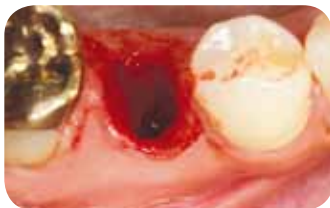In recent years, a variety of treatment concepts has been developed to prevent/minimize the loss of hard and soft tissue structures following tooth extraction and to create optimal conditions for the later implantation or conventional prosthetic restoration.

The socket seal technique aims at the maintenance of the soft tissue volume. After an atraumatic tooth extraction, the socket is closed with a soft tissue graft. The extraction socket may also be filled with a grafting material prior to grafting. The sealing stabilizes the blood clot, while the grafting material (if used) protects the socket from contamination and helps to maintain the topography of the alveolus.

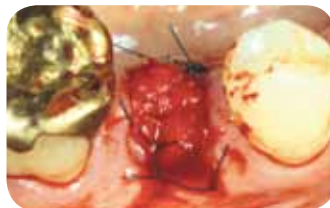An autologous mucosal transplant harvested with a punch from the palate is typically used to close the alveolus. In this situation, mucoderm® may be applied as an alternative that spares the patient the harvesting of the graft. Following rehydration, the matrix may be easily cut-to-shape and sutured to the marginal gingiva. For this particular indication, botiss has designed a circular mucoderm® matrix that can be easily applied during the socket seal technique and does not need further cutting.

## Application of mucoderm® in the socket seal technique

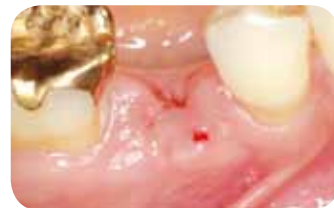### Clinical case Dr. Michael Back, Munich, Germany



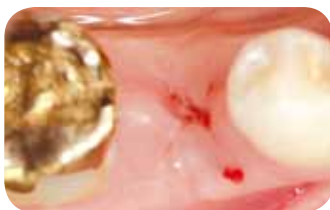
Atraumatic tooth extraction; the walls of the extraction socket are intact



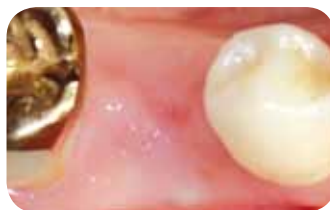The socket is sealed with mucoderm®, fixed with single sutures to the marginal gingiva



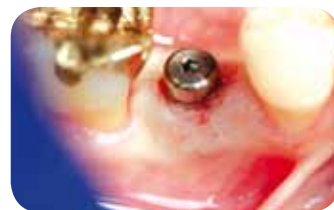Situation after healing, seven days post-extraction



Situation after ten days healing, occlusal view



Excellent soft tissue situation eight weeks after extraction at time point of implantation



Situation four months after extraction, insertion of healing cap

# Indications for mucoderm®



## Periodontology

mucoderm® is indicated for guided tissue regeneration procedures, in periodontal- and soft tissue recession defects.

The graft may be applied in the

- Coronally advanced flap technique
- Laterally advanced flap technique
- Envelope technique
- Tunnel technique



## Implantology, Oral Surgery and CMF

- Soft tissue augmentation/thickening
- Augmentation of the attached gingiva (free-gingival graft substitute)
- Covering of implants placed in immediate- or delayed extraction sockets
- Localized ridge augmentation for later implantation
- Alveolar ridge reconstruction for prosthetic treatment

## Product Specifications

Art.-No.	Dimensions	Content
701520	15 × 20 mm	1 × matrix
702030	20 × 30 mm	1 × matrix
703040	30 × 40 mm	1 × matrix
710210	Ø 10 mm	1 × punch



dental  
bone & tissue  
regeneration

botiss  
biomaterials

Innovation.  
Regeneration.  
Aesthetics.

soft tissue

education

hard tissue

botiss biomaterials GmbH  
Hauptstr. 28  
15806 Zossen / Germany

Tel.: +49 33769 / 88 41 985  
Fax: +49 33769 / 88 41 986

contact@botiss.com  
www.botiss.com  
www.facebook.com/botissdental